

Osteoarthritis and Cartilage



Brief Report

Synovial incorporation of polyacrylamide hydrogel after injection into normal and osteoarthritic animal joints



L. Christensen †*, L. Camitz ‡, K.E. Illigen §, M. Hansen ||, R. Sarvaa ¶, P.G. Conaghan #

† Department of Pathology, Herlev Hospital, University of Copenhagen, Denmark

‡ Camitz Equestrian, Glumsoe, Denmark

§ Statens Serum Institut, Copenhagen, Denmark

|| Hojgaard Horse Hospital, Fuen, Denmark

¶ Felina Cat Clinic, Copenhagen, Denmark

Leeds Institute of Rheumatic and Musculoskeletal Medicine, University of Leeds and NIHR Leeds Musculoskeletal Biomedical Research Unit, Leeds, UK

ARTICLE INFO

Article history:

Received 11 March 2016

Accepted 19 July 2016

Keywords:

Osteoarthritis

Synovial incorporation

Polyacrylamide hydrogel

SUMMARY

Objective: Polyacrylamide hydrogel (PAAG) is a non-toxic, non-degradable synthetic product, used for years in the augmentation of soft tissues. Preliminary results in animals and humans have suggested long-lasting beneficial effects on symptoms of osteoarthritis (OA). The aim of this histopathological study was to investigate whether intra-articular injection of PAAG is integrated into synovial tissue in normal and OA animal joints, and if this integration is sustained.

Methods: (A) A prospective, controlled, longitudinal study of normal knee joints injected with PAAG was performed in 10 rabbits, following the animals up to 1 year, and (B) a post mortem examination was carried out up to 2 years post-injection on 18 horse joints which had previously been treated with 1–2 injections of 2 ml PAAG for clinically and radiologically diagnosed OA.

Results: Integration of the injected gel was evident at day 10 in the rabbit and by day 14 in the horse, with proliferation and invasion of synovial cells into the gel. By day 90 in rabbit joints and day 30 in horse joints, the gel had formed a sub-synovial layer, which was traversed by thin strands of connective tissue with vessels and covered by a synovial lining facing the joint cavity. This histological appearance persisted up to 2 years post-injection in horse joints.

Conclusion: Intra-articular injection of PAAG results in a stable, long-lasting sub-synovial layer of gel traversed with thin strands of connective tissue. Further studies to explore potential effects on synovial inflammation and pain are warranted.

© 2016 The Author(s). Published by Elsevier Ltd on behalf of Osteoarthritis Research Society International. This is an open access article under the CC BY-NC-ND license (<http://creativecommons.org/licenses/by-nc-nd/4.0/>).

Introduction

Osteoarthritis (OA) represents a major health problem compounded by aging and increasingly obese populations and is the fastest growing cause of global disability¹. Current treatments are focused on reducing symptoms, and there are few effective therapies. Most people with OA have persistent pain despite use of all prescribed therapies^{1,2}. Current pharmacological treatments are

associated with significant toxicities and contra-indications, and their use is restricted across populations^{1,2}. There is therefore a major need to develop new analgesic therapies for OA.

Polyacrylamide hydrogel (PAAG) (Contura International A/S, Soborg, Denmark) is a synthetic, non-degradable hydrogel, which is biocompatible and non-toxic³ with water exchanging abilities⁴. The hydrogel has been used for years in the augmentation of soft tissues such as skin and bladder neck^{5–9}, and histopathological studies of soft subcutaneous tissues from mice³, rats⁵, rabbits⁶, pigs¹⁰ and humans¹¹ have shown that it supports cellular growth and integration, and possesses a permanent and stable augmentation effect due to the constant molecular water exchange with its host tissue⁴.

PAAG is also known for its ability to allow in-growth of host tissue cells *in vivo*. The tissue integration begins immediately after gel injection as a sort of foreign body reaction to the PAAG. Host

* Address correspondence and reprint requests to: L. Christensen, Department of Pathology, Herlev Hospital, Herlev Ringvej 75, 2730 Herlev, Denmark.

E-mail addresses: lise.christensen.01@regionh.dk (L. Christensen), Camitz@mail.dk (L. Camitz), KEI@ssi.dk (K.E. Illigen), kontakt@hoejgaard-hestehospital.dk (M. Hansen), Dyredoktor@hotmail.com (R. Sarvaa), P.Conaghan@leeds.ac.uk (P.G. Conaghan).

macrophages and foreign-body giant cells initially surround the gel and then invade it. In the process these cells are gradually transformed into fibroblasts and endothelial cells, which eventually form a thin vessel-bearing fibrous network inside the gel¹⁰.

In a preliminary study, PAAG demonstrated analgesic benefits in equine OA joints up to 2 years post injection¹². In order to understand any potential mechanism of action of PAAG, the first step would be to demonstrate if the gel was retained over the duration of purported benefit, and where the gel would be located following injection (joint cavity or tissues). The main purpose of this histopathological study was therefore to investigate the fate of the gel following injection, and the secondary aims were to determine the duration of retention and possible tissue distribution at different times after intra-articular injection of PAAG in normal and OA animal joints.

Methods

Two animal joint types were examined. Firstly, we conducted a prospective, longitudinal, controlled study on normal knee joints in rabbits, and secondly, a post mortem examination was made on OA horse joints which had been treated with PAAG at different times prior to death. The PAAG used in all these cases was Aquamir Reconstruction® (Contura International A/S, Soeborg, Denmark). Ethical approval was obtained from the Danish Animal Welfare Organization (dyreforsøgstilsynet, reference J.nr. 2010/561-1774).

Prospective comparative study in normal rabbit joints

A total of 10 two-year old New Zealand white rabbits were used. The first four received injections in the right knee with 2.5% PAAG and in the left knee saline as control. The remaining six rabbits also received PAAG injections in the right knee but in the left knee they received hyaluronic acid gel (HAG, Durolane 20 mg/ml, Galderma, Switzerland) as a control. The volume of injected PAAG, saline or HAG was 0.3 ml per knee. This was administered after having removed a few drops of joint fluid to ensure correct position of the injection needle. The rabbits were observed daily for well-being and their weight was measured once a week and they were kept under standard conditions in pairs. The first four rabbits (saline control group) were sacrificed after 10 days. The remaining six rabbits were sacrificed, two at a time, after 3, 6 and 12 months. For all 10 rabbits both knee joints were removed and inspected macroscopically. All synovial, cartilage, tendon and fatty tissue of the joint was removed and processed for histopathological examination using H&E and van Gieson/Alcian blue stains as tissue markers.

A study of osteoarthritic joints in the horse

This study included seven horses (age 5–13 years, median 10 years) presenting a total of 13 joints with veterinarian-diagnosed OA that had been treated with PAAG. Five joints without OA served as controls. The horses were part of a large prospective clinical study carried out at three different equine centers, where 1–4 (mean 2) ml of PAAG had been injected per joint and where the effect of the treatment was followed postoperatively for up to 2 years¹². Histopathological examination was carried out on leg joints from horses having died during that period. Treatment with PAAG had been performed from 7 days to 2 years previously. All horses had been euthanized for causes unrelated to the PAAG treatment. After dissection and macroscopic inspection of the joints, all synovial tissue representing the inner capsule was routinely fixed, paraffin embedded and stained for light microscopy. Samples from the cartilage were also examined (two from each joint).

Results

Rabbit study

The rabbits with normal joints were all healthy at injection and remained so during the study with no change in joint movement (e.g., activity restriction or limping) at any time.

On gross inspection there were no differences other than two cases of slight capsule hemorrhage at injection site. Upon opening the joint cavity, the synovial fluid was more viscous, and the inner synovial lining appeared slightly thickened on the PAAG-treated side as compared to the saline-treated side at day 10. No macroscopic differences could be discerned between PAAG and HAG treated joints at any time point.

Light microscopy on the PAAG treated side at day 10 showed a synovial lining layer which was 5–10-fold thicker than on the saline injected side, due to the gel containing proliferating synovial cells [Fig. 1(a) and (b)].

At 3, 6 and 12 months the synovial layer was still up to 10-times thickened on the PAAG treated side [Fig. 1(c)], and the synovial lining was present on top of the gel facing the cavity [Fig. 1(c)]. By now only scattered synovial cells were seen inside the gel intermixed with a fine fibrous network. PAAG was no longer seen within the cavity, but on the HAG treated side a minimal amount of a dense homogenous blue material thought to be a remnant trace of Durolane was seen at 3 months in one of the synovial foldings [Fig. 1(d)]. This was not seen at 6 and 12 months.

Horse study

Macroscopic findings

Coffin, fetlock and knee joints had been treated with PAAG. Three untreated coffin joints and two fetlock joints served as controls. Upon opening the joint cavity, various grades of osteophyte formation and/or cartilage defect(s) could only be seen in three of the five treated fetlock joints. The PAAG appeared as a thick, smooth, glistening, yellow substance or in the coffin joint as small clear deposits along the inner part of the anterior longitudinal tendon facing the cavity. Free PAAG inside the cavity could not be discerned from joint fluid on naked eye inspection.

Light microscopy findings

In the short term, 1 and 2 weeks post treatment, the PAAG appeared as an inner layer within the synovial lining intermixed with proliferating synovial cells, similar to the histology seen in the rabbit model. At 1 month the synovial cells had apparently relocated towards the surface, and at 3 months a distinct layer of synovial cells had formed on top of the integrated PAAG [Fig. 2(a)]. The same pattern was found at 8 months and at 24 months [Fig. 2(c) and (d)]. In general, there was no reduction in membrane thickness of the integrated gel, and at higher magnification, it could be seen by H&E morphology that the PAAG had materialized itself as a thick integrated zone with at first scattered mononuclear inflammatory cells, possibly synovial cells [Fig. 2(a)], and later with a fine fibrous network and very few of these inflammatory cells [Fig. 2(d)].

Discussion

This histopathological study investigating the location and retention of PAAG in joints with and without OA has revealed that PAAG appears to form a sub-lining layer. All examined joints from both species showed the same PAAG integration into the inner layer of the synovium and the re-location of the synovial cells on the surface. Furthermore, we found that integrated PAAG was

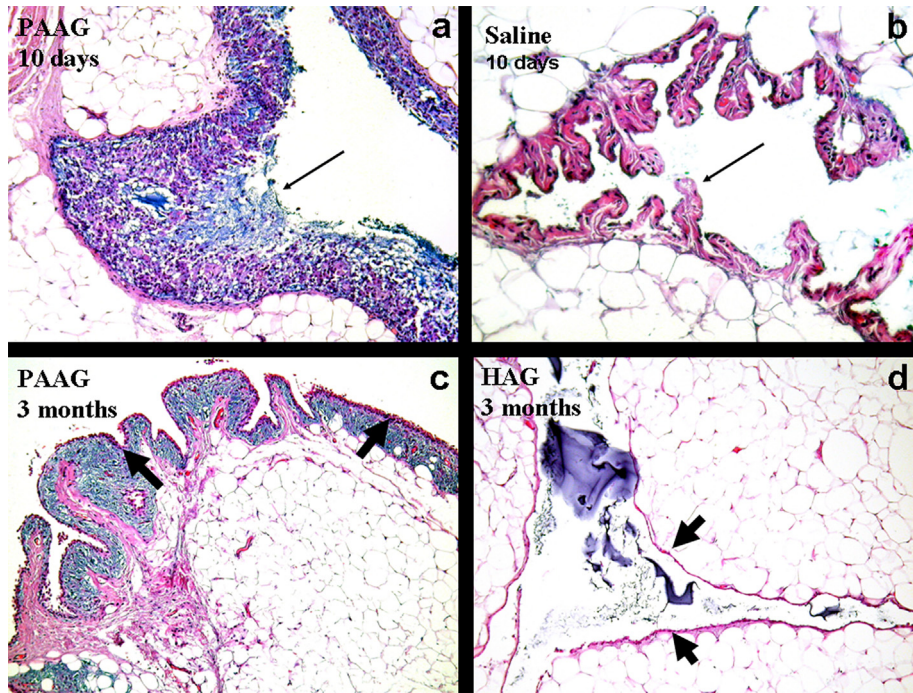


Fig. 1. Rabbit normal knee joint injected with PAAG and saline after 10 days (a, b) and with PAAG and HAG after 30 days (c, d). At 10 days the blue gel was still lying in the cavity, where it was dominated by proliferating synovial cells (a, thin arrow). Normal synovium was seen on the saline injected side (b, thin arrow). At 3 months the synovial lining was intact (c) on top of a layer of blue PAAG containing scattered chronic inflammatory cells intermixed with a fine fibrous network (fat arrows). There was no PAAG in the cavity, but traces of a HAG-like material were seen within the cavity in a few of the synovial folds (d, fat arrows). HE $\times 400$ (a, b), HE $\times 200$ (c, d).

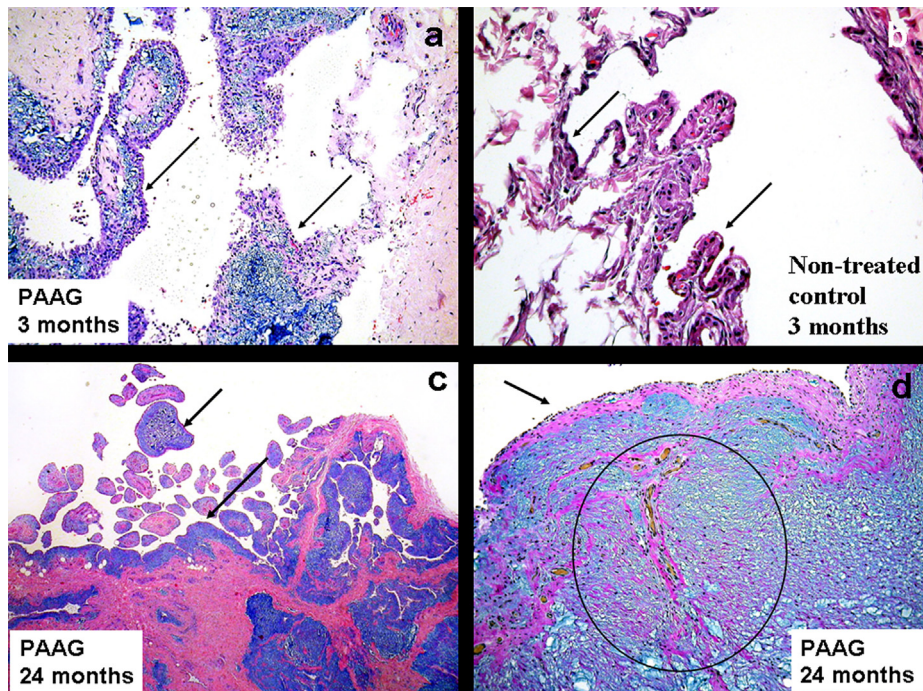


Fig. 2. Horse fetlock joint treated with PAAG for OA after 3 months (a) and after 24 months (c, d). Non-treated fetlock synovial control tissue is shown in b. The synovial surface lining is marked with arrows. The fine fibrous network with blood vessels inside the gel at 24 months is circled in d. HE $\times 200$ (a, b), HE $\times 60$ (c), and van Gieson/Alcian blue $\times 150$ (d).

unaltered after at least 2 years. The subsynovial zone retained its thickness.

The main differences between the integration of PAAG in previous tissues and the synovial membrane of the present study is that the previous studies were not associated with any luminal surfaces and the gel contained macrophages and giant cells up until

14 months post injection¹⁰. The current study uniquely demonstrated the formation of a novel synovial lining layer after integration of the PAAG, and no giant cells at any time [Figs. 1(a), (c) and 2(a), (c), (d)].

Analgesic benefits for PAAG have been reported in an observational study in the horse, where one treatment of 2 ml PAAG in

fetlock or carpus joints was found to have a significant effect on lameness and effusion during the first month post treatment, after which this effect increased progressively until 6 months, and then stabilized up until 24 months¹². Recently an observational pilot study of 60 human knees with OA, which were treated with non-degradable PAAG, showed promising results for pain reduction¹³. It is interesting to speculate on potential mechanisms by which PAAG may produce an analgesic effect, and the effects of the sub-lining layer of PAAG are not clear from this work. There may be changes to synovial cell composition or cytokine production, and/or mechanical properties of the synovium. This will require further investigation, as this study has several limitations including a limited number of experimental animals, different types of horse joints, variations in PAAG doses and different time periods of follow up.

In conclusion, intra-articular PAAG is present in joint synovium and persists over a time course consistent with reported analgesic benefits in observational animal and human studies. In parallel with ongoing clinical studies of efficacy, further studies are needed to explain its potential mechanism of action.

Disclosures

Lise H. Christensen is consultant for Contura and Galderma.

Philip G. Conaghan is consultant or speakers bureau for Abbvie, Contura, Flexion, Lilly, Pfizer, Roche, Novartis.

Linus Camitz and Michael Hansen have been clinical investigators for Contura.

Kristin Engelhart Illigen and Raiku Sarvaa have nothing to declare.

Author contributions

Conception and design of the study (Lise Christensen, Linus Camitz, Kristin Engelhart Illigen, Michael Hansen, Raiku Sarvaa).

Acquisition of data (Lise Christensen, Raiku Sarvaa, Linus Camitz).

Analysis and interpretation of data (Lise Christensen).

Drafting and revising the article critically for important intellectual content (Philip Conaghan).

Acknowledgements

Contura International A/S, Sydmarken 3, Soeborg, Denmark is thanked for providing the polyacrylamide gel used for both studies as well as all expenses (acquisition and housing) for the rabbits. Statens Serum Institute, Denmark, is thanked for permitting housing of the rabbits. Bente Brønner is thanked for helping Raiku Sarvaa, Linus Camitz and Michael Hansen in bringing rabbit and horse legs to Bispebjerg Hospital, Copenhagen, Denmark, for histopathological examination and tissue processing.

References

- Glynn-Jones S, Palmer AJR, Agricola R, Price AJ, Vincent TL, Weinans H, et al. Osteoarthritis. *Lancet* 2015;25:376–87.
- Wenham CYJ, Conaghan PG. The role of synovitis in osteoarthritis. *Ther Adv Musculoskel Dis* 2010;2:349–59.
- Zarini E, Supino R, Pratesi G, Laccabue D, Tortoreto M, Scanziani E, et al. Biocompatibility and tissue interactions of a new filler material for medical use. *Plast Reconstr Surg* 2004;114:934–42.
- Brahm J, Lessel R, Ditlev S, Schmidt R. Flux of selected body fluid constituents and benzylpenicillin in polyacrylamide hydrogel (PAAG). *J Tissue Eng Regen Med* 2012;6:793–802.
- Fernandez-Cossio S, Castano-Oreja MT. Biocompatibility of two novel dermal fillers: histological evaluation of implants of a hyaluronic acid filler and a polyacrylamide filler. *Plast Reconstr Surg* 2006;117:1789–96.
- Bello G, Jackson IT, Keskin M, Kelly C, Dajani K, Studinger R, et al. The use of polyacrylamide gel in soft-tissue augmentation: an experimental assessment. *Plast Reconstr Surg* 2007;119:1326–36.
- Narins RS, Coleman 3rd WP, Rohrich R, Monheit G, Glogau R, Brandt F, et al. 12-Month controlled study in the United States of the safety and efficacy of a permanent 2.5% polyacrylamide hydrogel soft-tissue filler. *Dermatol Surg* 2010;36(Suppl 3):1819–29.
- Pallua N, Wolter TP. A 5-year assessment of safety and aesthetic results after facial soft-tissue augmentation with polyacrylamide hydrogel (Aquamid): a prospective multicenter study of 251 patients. *Plast Reconstr Surg* 2010;125:1797–804.
- Sokol ER, Karram MM, Dmochowski R. Efficacy and safety of polyacrylamide hydrogel for the treatment of female stress incontinence: a randomized, prospective, multicenter North American study. *J Urol* 2014;192:843–9.
- Christensen LH, Nielsen JB, Mouritsen L, Sorensen M, Lose G. Tissue integration of polyacrylamide hydrogel: an experimental study of periurethral, perivesical, and mammary gland tissue in the pig. *Dermatol Surg* 2008;34:S68–77.
- Christensen L, Breiting V, Bjarnsholt T, Eickhardt S, Høgdall E, Janssen M, et al. Bacterial infection as a likely cause of adverse reactions to polyacrylamide hydrogel fillers in cosmetic surgery. *Clin Infect Dis* 2013;56:1438–44.
- Tnibar A, Schougaard H, Camitz L, Rasmussen J, Koene M, Jahn W, et al. An international multi-centre prospective study on the efficacy of an intraarticular polyacrylamide hydrogel in horses with osteoarthritis: a 24 months follow-up. *Acta Vet Scand* 2015;57:20 (8 pp).
- Hartkopp A. Injection of Non-degradable Polyacrylamide Gel into the Knee Joint Shows Long-term Effect on Osteoarthritis Symptoms – A Pilot Study 2016 (Manuscript in preparation).